

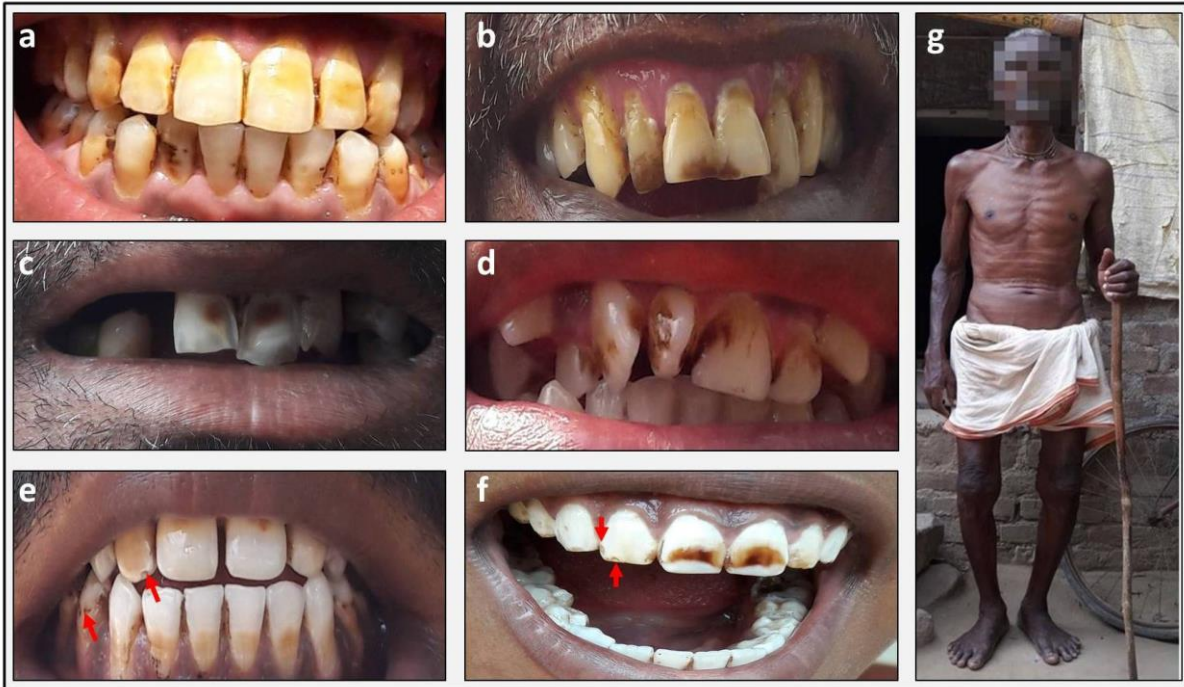Figure 1. Moderate form of dental fluorosis (a-d), severe form of dental fluorosis (e-f, red arrow indicates pitting) and skeletal fluorosis (g).

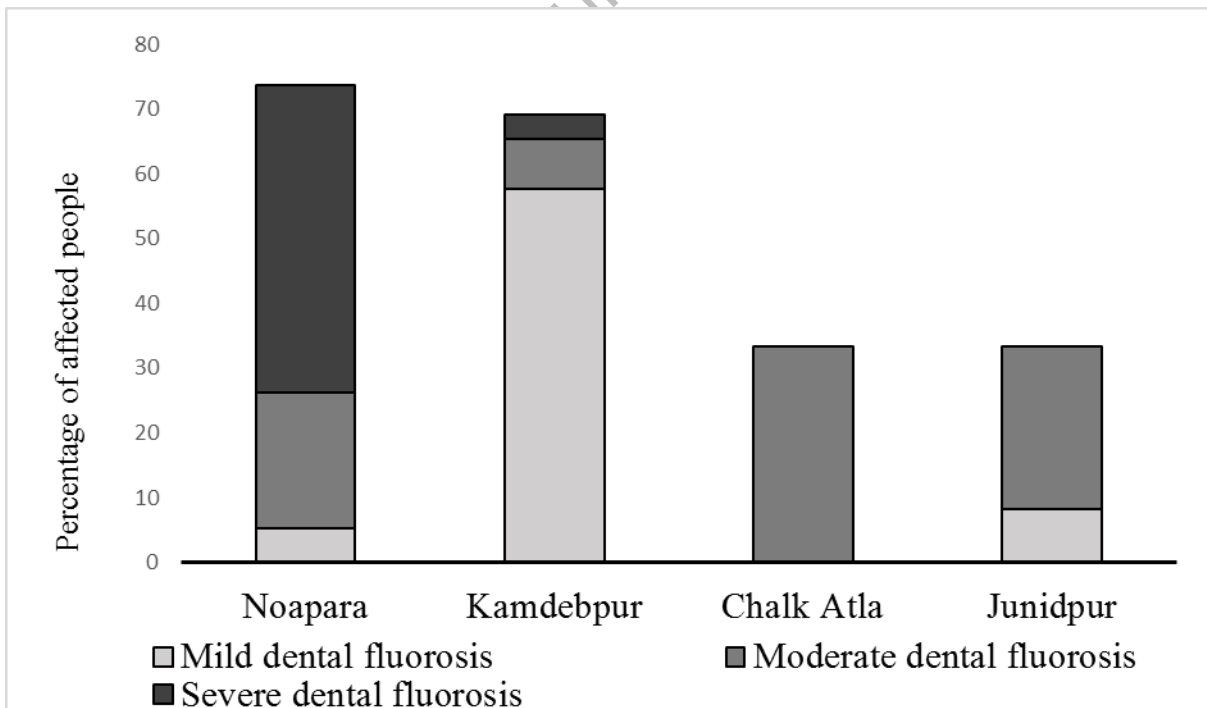


Figure 2. Graph showing the percentage of subjects suffering from dental fluorosis.