

elevation of all fractions as compared to the latter. Apart from these, the present technique gives quantitative data in less than an hour, a thing which cannot be done by using conventional techniques.

Thus the advantage of cellulose acetate electrophoresis of CSF proteins lies in the fact that valuable information could be got for purposes of diagnosis and management with speed and accuracy. In some of the CNS disorders seen in relatively large numbers in tropical countries and where early diagnostic formulations would help in therapeutic management, the present technique is found to provide valuable information.

Dept. of Neurochemistry, M. N. SUBHASH.
National Inst. of Mental B. S. SRIDHARA RAMA RAO.
Health and Neuro Sciences,
Bangalore, July 9, 1979.

* Gifts of WHO-SEARO.

1. Gebott, D. M., *Beckman Microzone Electrophoresis Manual*, Beckman Instruments, California, USA, 1977.
2. Jensen, K., "Cerebrospinal fluid proteins in neurological diseases," *Acta Neurol. Scand. Suppl.*, 1978, 58 (70).
3. Lowenthal, A., *Agargel Electrophoresis in Neurology*, Elsevier Publishing Co., New York, 1964.
4. Smith, I., *Chromatographic and Electrophoretic Techniques*, William Heinemann, 1968, 2.

A PRELIMINARY OBSERVATION ON THE ACTION OF METOCLOPRAMIDE ON SKELETAL MUSCLE OF FROG AND GUINEAPIG ILEUM

METOCLOPRAMIDE is one of the recently introduced antiemetic. It promotes oesophageal and gastric peristalsis, increases the tone of the cardiac sphincter and tends to speed gastric emptying. Extrapyramidal reaction is one of the few side effects produced by this drug. Its therapeutic actions are antagonised by anticholinergic drugs like atropine¹⁵. It has been reported, that the drugs inducing extrapyramidal reactions like chlorpromazine¹, chloroquine^{2,3}, quinine, morphine⁴, atropine^{5,6}, some of the antihistamines⁶, other phenothiazines, ergot alkaloids⁹ and metallic tremorogens like copper, mercury, lead and manganese (unpublished data), when tested on rectus abdominis muscle of frog, exhibit a curarimimetic as well as a cholinomimetic effect. On superfused intestine, produce a contraction and also potentiate acetylcholine (Ach)^{6,10}. Since, metoclopramide is also a tremorogen¹³, the present study was undertaken to test whether it produces similar response on the biological preparations mentioned above.

The rectus abdominis muscle of frog was superfused as reported earlier⁴. After recording sub-

maximal response of the tissue to Ach, metoclopramide was added in 1, 10, 100 ng and 1, 10 and 100 mcg concentrations, followed by Ach. The guineapig ileum was superfused as reported from our laboratory^{6,8}. Metoclopramide was used in the same concentrations as mentioned above. The response of the tissue was recorded on a slow moving smoked drum. Atropine sulphate was used as an antagonist.

On skeletal muscle, the metoclopramide in 1, 10 and 100 ng concentrations produced an unpredictable effect on the action of Ach, *i.e.*, sometimes an immediate potentiation of Ach, a curarimimetic effect and a delayed potentiation of Ach. Whereas in 1, 10 and 100 mcg concentrations it produced a predictable and graded potentiation of Ach (Fig. 1); at 100 mcg concentrations the tissue responded with a maximum contraction, and during recovery Ach was potentiated. The guineapig ileum responded with a contraction to all concentrations of metoclopramide in a graded fashion. Ach was also potentiated (Fig. 2). Atropine which is reported to exhibit a dual action on intestinal smooth muscle⁶, produced a contraction of guineapig ileum (Fig. 2) but blocked the contraction induced by metoclopramide partially and with increasing concentrations completely.




FIG. 1. Showing effect of metoclopramide on rectus abdominis muscle of frog, all contractions are induced by 0.1 mcg of Ach, 1 and 10 indicate the addition of 1 and 10 mcg of metoclopramide followed by Ach.

Metoclopramide has been reported to potentiate Ach on human intestine¹⁴. It potentiates Ach on skeletal muscle of frog and guineapig ileum and produces contraction of the latter which is antagonised by atropine (Figs. 1 and 2). The therapeutic action of metoclopramide is antagonised by anticholinergic drugs¹⁶. Its mechanism of antiemetic effect is due to the increasing gastric peristalsis and frequent gastric emptying. Our results indicate that it has produced similar effect on both skeletal muscle as well as on intestinal smooth muscle like other tremorogens reported from our laboratory. Though it is said to induce extrapyramidal reactions by antagonising

depaminergic receptors, involvement of a direct cholinergic effect of the drug cannot be ruled out. Because, after large oral dose it produces deterioration in Parkinson's patients and the drugs used in the treatment of extrapyramidal reactions induced by metoclopramide are anticholinergic in nature¹³ and cholinomimetic drugs are tremorogens¹⁵. Thus, it appears, the extrapyramidal reactions induced by metoclopramide may be an extension of its therapeutic action.

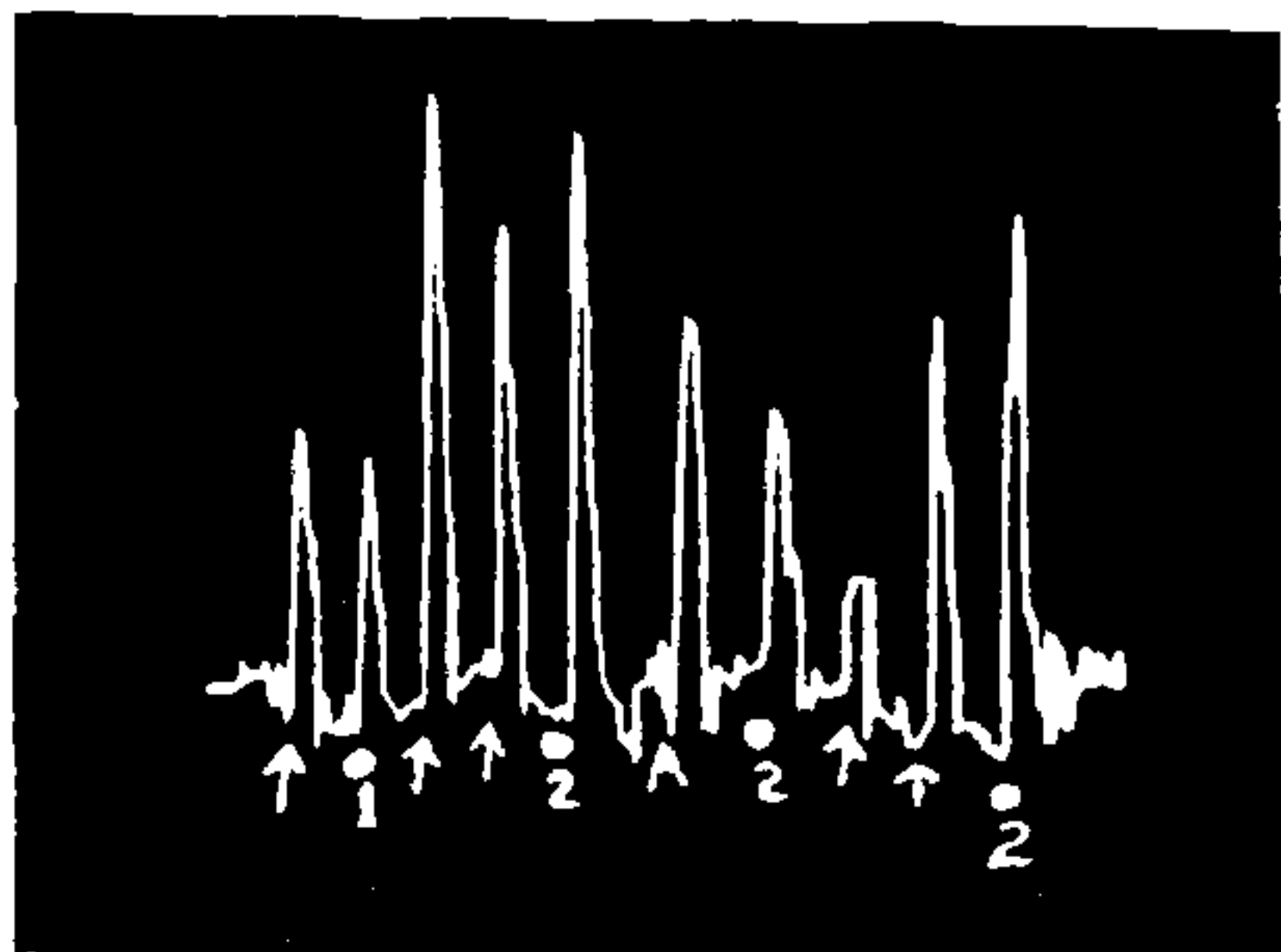


FIG. 2. Showing the action of metoclopramide on guineapig ileum, arrow indicates the addition of 1 pg of Ach, 1 and 2 indicate, 1 and 10 ng of metoclopramide only. A-0.1 mcg of Atropine. Note the contraction induced by atropine, after which 10 ng of metoclopramide and Ach are partially blocked.

Authors gratefully acknowledge the gift of metoclopramide by M/s. IPCA Laboratories Pvt. Ltd., Bombay. They are grateful to Prof. Dr. L. B. Gopalakrishna Murthy and Dr. G. R. Chandrasekhar for their encouragement and to Dr. H. Gurupadappa, Principal, for his keen interest.

Department of Pharmacology, S. R. K. ACHARYA,*
J. J. M. Medical College, T. N. KUMAR.
Davangere 577 004,
December 19, 1979.

* Present address: Research Scholar, Department of Pharmacology, P.G. Institute of Basic Medical Sciences, Taramani, Madras 600 042.

1. Acharya, S. R. K. and Rao, A. R. G., *Curr. Sci.*, 1975, 44, 147.
2. — and Rao, S. Arogya, *J. Health Sci.*, 1976, 2, 123.
3. — and Rao, S., *J. Ind. Med. Asso.*, 1979, 72, 68 (Letter).
4. — and Rao, A. R. G. Arogya, *J. Health Sci.*, 1975, 1, 69.
5. — and Rao, S., *Ind. J. Pharmac.*, 1977, 9 (3), 185.
6. — and —, *J. Postgrad Med.*, 1979, 25 (1), 12.

7. Acharya, S. R. K. and Rao, A. R. G., *Curr. Sci.*, 1977, 23 (4), 168.
8. — and Rao, S. Arogya, *J. Health Sci.*, 1979, 5, 57.
9. —, Paper presented before Southern Regional Conferences of IPS, Sept. 1977, Mangalore.
10. —, Paper presented before Southern Regional Conference of IPS, September 1977, Kurnool.
11. Akindele, M. O. and Odejide, A. O., *Brit. Med. J.*, 1976, 2, 214.
12. Umez-Eronini, E. M. and Eoronini, E. A., *Ibid.*, 1977, 1, 945.
13. Kataria, K., Traub, M. and Marsden, C. D., *Lancet*, 1978, 2, 1254.
14. Eisner, M., *Brit. Med. J.*, 1968, 4, 679.
15. Wade, A. and Reynolds, J. E. F., *Martindale Extraparmacopoeia*, Pharmaceutical Press, London, 1977, p. 934.
16. Brimble Combe, R. W. and Pinder, R. M., *Tremors and Tremorogenic Agents*, Scientechica (Publishers), Bristol, 1972, p. 94.

THE OCCURRENCE OF GABBROIC INTRUSION IN DECCAN TRAP BASALTS NEAR KHOPOLI IN THE KONKAN AREA (MAHARASHTRA)

WHILE interpreting the aerial photographs of Lonavala, Khandala and Khopoli area (Maharashtra), a medium grey toned low lying ridge, extending in ENE-WSW direction was noted about 3 km west of Khopoli (73° 21' E, 18° 47' N). The ridge shows distinct relief on the aerial photographs (scale 1 : 22700). The area around this ridge is covered by paddy fields and exhibits light tone on aerial photographs. The country rock, Deccan Trap basalts, wherever exposed, also show slightly lighter tone than the ridge. Seven basic dykes, which occur in this area, have produced three different types of lineaments on aerial photograph¹. The linear valley controlled by dyke No. 4 has given rise to a negative lineament while dyke No. 5, which formed low lying linear ridge, appeared as a positive lineament on aerial photograph. All other dykes are more or less at the ground level and produced tonal lineaments, either light toned when the dyke is covered by dry grass or dark toned when the dyke is barren. Field checks revealed that the ridge is due to a coarse grained melanocratic rock which has clear cut discordant relationship with the associated Deccan Trap basalt flows. The intrusive body has lenticular outcrops which extend for about 3 to 4 km in length and with a maximum width of about 1/2 km (Fig. 1). On following the gabbro body towards SW, it was found that the country rock has been fractured with individual master joints trending in ENE-WSW direction. Further towards SW it was observed that a tributary of Patalganga river, near